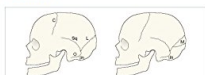

[PDF] Accident And Emergency Radiology: A Survival Guide, 3e

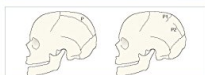Nigel Raby FRCR, Laurence Berman MB BS FRCP FRCR, Simon Morley FRCR, Gerald De Lacey MA FRCR - pdf download free book

Accident and Emergency Radiology: A Survival Guide, 3rd Edition, ISBN: 9780702042324, CD-ROM Edition
Paediatric skull—suspected NAI

The lateral SKR

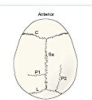


The normal sutures: L = lambdoid suture, C = coronal suture, M = mastoid, S = sphenoidal suture, P = parietal suture, P = parietal suture



Accessory parietal sutures. Can appear in various positions (P)

Accessory parietal sutures may be positioned. This drawing does not correspond to any radiographic projection. It shows the general positions and direction of the suture lines. The suture lines are shown in grey and P2 when looking down from above the coronoid.



37

Books Details:

Title: Accident and Emergency Radiol

Author: Nigel Raby FRCR, Laurence Be

Released:

Language:

Pages: 364

ISBN: 0702042323

ISBN13: 9780702042324

ASIN: 0702042323

[**CLICK HERE FOR DOWNLOAD**](#)

pdf, mobi, epub, azw, kindle

Description:

Since it was first published, Accident and Emergency Radiology: A Survival Guide has become the classic in-my-pocket-reference and an indispensable aid to all those who work in the Emergency

Department. The core and substantial value lies in the step-by-step analytical approaches which help you to answer this question: "These images look normal to me, but . . . how can I be sure that I am not missing a subtle but important abnormality?"

"This book will provide essential reading and support to A&E trainees, medical students, radiology trainees, reporting radiographers and clinical nurse specialists, all of whom may be faced with trauma cases requiring accurate diagnosis and treatment." **Reviewed by:** RAD Magazine Feb 2015

"... Very nearly flawless...contains just the right amount of information to accommodate readers from trainees through to consultant or attending level." **Reviewed by** African Journal of Emergency Medicine , Jun 2015

- Ensure accuracy in reading and interpretation of any given image. Common sources of error and diagnostic difficulty are highlighted.
 - **Prevent mistakes.** Pitfalls and associated abnormalities are emphasized throughout.
 - **Avoid misdiagnoses.** Normal anatomy is outlined alongside schemes for detecting variants of the norm. Each chapter concludes with a summary of key points. Will provide a useful overview of the most important features in diagnosis and interpretation.
 - **Easily grasp difficult anatomical concepts.** Radiographs accompanied by clear, explanatory line-drawings.
 - Spend less time searching with an improved layout and design with succinct, easy-to-follow text. A templated chapter approach helps you access key information quickly. Each chapter includes key points summary, basic radiographs, normal anatomy, guidance on analyzing the radiographs, common injuries, rare but important injuries, pitfalls, regularly overlooked injuries, examples, and references.
 - **Grasp the nuances of key diagnostic details.** Updated and expanded information, new radiographs, and new explanatory line drawings reinforce the book's aim of providing clear, practical advice in diagnosis.
 - **Avoid pitfalls** in the detection of abnormalities that are most commonly overlooked or misinterpreted.
 - **Access the complete contents** and illustrations online at **Expert Consult**—fully searchable!
-

- Title: Accident and Emergency Radiology: A Survival Guide, 3e
- Author: Nigel Raby FRCR, Laurence Berman MB BS FRCP FRCR, Simon Morley FRCR, Gerald de Lacey MA FRCR
- Released:
- Language:
- Pages: 384
- ISBN: 0702042323
- ISBN13: 9780702042324
- ASIN: 0702042323

